

Double Banded Space Regainer (DBSR) in Distalising Two Teeth- A Case Report

Patil Disha¹, Bharath K P², Poornima P³, Praveen Bali⁴

1-Senior Lecturer, Vivekanadha dental college for women, Elayampalayam, Thiruchengode, Namakkal dist, Tamil Nadu, India. 2-Reader, department of Pedodontics, College of Dental Sciences, Davangere, Karnataka, India. 3-Professor and head, department of Pedodontics, College of Dental Sciences, Davangere, Karnataka, India. 4- Senior Lecturer , department of Pedodontics, College of Dental Sciences, Davangere, Karnataka, India.

Correspondence to:
Dr. Patil Disha, Senior Lecturer, Vivekanadha dental college for women, Elayampalayam, Thiruchengode, Namakkal dist, Tamil Nadu, India.
Contact Us: www.ijohmr.com

ABSTRACT

The premature loss of primary first molar can lead to mesial migration of the primary second molar and first permanent molar as well and disturb the integrity of arch. The consideration at this point should be to move the teeth and recover the space lost for the eruption of the permanent successor. The present article describes a case of space regaining, judiciously accomplished with the distal movement of two teeth using double banded space regainer incorporating NiTi springs.

KEYWORDS: Double banded space regainer, NiTi, Two teeth distalisation

INTRODUCTION

The importance of healthy and well aligned primary teeth lays a foundation for the future dental health of the child. An important aspect of this includes proper handling of space created by the premature loss of deciduous teeth. The technique of space management is an art of treating space discrepancy problems in mixed dentition (e.g., maintenance of leeway space). An integral part of mixed dentition protocol is monitoring the transition from the mixed to the permanent dentition.¹ When the normal sequence of exfoliation of primary teeth and eruption of permanent teeth does not happen, it must caution the clinician of supervising and initiating preventive orthodontic procedures with space maintainers. If space maintenance is not carried out on the premature loss of deciduous molars, then an interceptive orthodontic procedure would have to be carried out with space regainers.² The goal of space regaining is to recover the lost arch width and perimeter.³

Space regainers can be broadly divided into fixed and removable type. Removable space regainers mostly use springs and screws to regain the lost space. Various fixed space regainers mentioned in literature are Open coil spring, Gerber's space regainer, Hotz lingual arch. Certain considerations for space regaining include; the alignment and space needs of other teeth in the arch, transverse, and sagittal dental relationship, also vertical relationship. Then the regained space is to be maintained. The treatment should be such that no further disharmonies develop. Hence, the following article describes a case of judicious use of double banded space regainer (DBSR)⁴ in regaining the space lost due to the untimely loss of primary first molar, and hence distalisation of two teeth to regain the lost space, i.e. primary second molar, and permanent first molar.

CASE REPORT

A seven-year old male patient reported to the department of pedodontics and preventive dentistry with a chief complaint of food lodgement in the lower left back teeth region. Past medical history was insignificant. Past dental history had shown that the patient underwent extraction i.r.t the upper left back tooth region. Upper left primary first molar (64) had been extracted a year ago, and the patient gave a history of extraction of the teeth due to decay, and space loss was observed (Figure 1a, 1b). Therefore, study models were made, and model analysis showed a space loss of 2.2 mm in the upper left quadrant. Therefore, it was decided to regain the lost space. The patient's chief complaint was attended and at the same time, his parents were informed about the space loss and its sequelae and the importance of timely intervention for the preservation of loss of arch length.

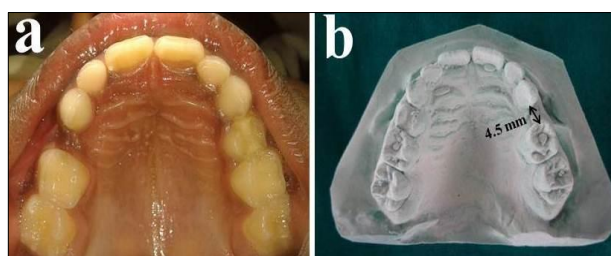


Figure 1a: preoperative photograph of the patient showing space loss in relation to maxillary left primary first molar. Figure 1b: preoperative photograph of the maxillary study model showing 4.5 mm space present between the maxillary left primary canine and primary second molar.

The space regainer designed to regain the space was same as that mentioned by Chalacka P et al.⁴ except for few changes which are as follows. The primary left second molar was banded (0.005 × 0.180 in) with molar tubes (0.7 mm diameter, 10 mm length) welded to it buccally

How to cite this article:

Patil D, Bharath KP, Poornima P, Bali P. Double Banded Space Regainer (DBSR) in Distalising Two Teeth- A Case Report. *Int J Oral Health Med Res* 2016;3(1):140-142.

and palatally. The primary left canine was also banded (0.005×0.180 in) with two stainless steel wires (0.7 mm width) soldered to it buccally and palatally, extending posteriorly to insert into the molar tubes of the primary second molar. NiTi open coil springs were cut 2-3mm longer than the distance between anterior stop (solder joints) and molar tubes posteriorly, and incorporated into the wires. The assembly was cemented on to the teeth with the springs held in compression to half their lengths (Figure 2). After 2 months, the space gained was 2.5 mm, hence the total space available between the primary left second molar and the primary left canine was 7 mm (Figure 3a, 3b). The appliance was replaced with a short band and loop soon after to maintain the regained space until the eruption of first premolar (Figure 4).

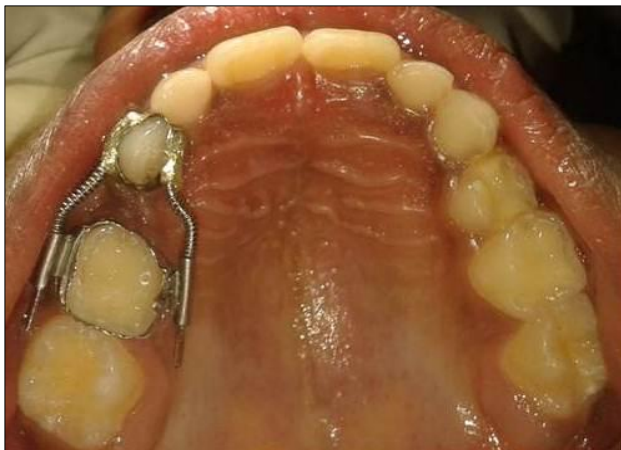

Figure 2: intraoral view of the appliance in place.

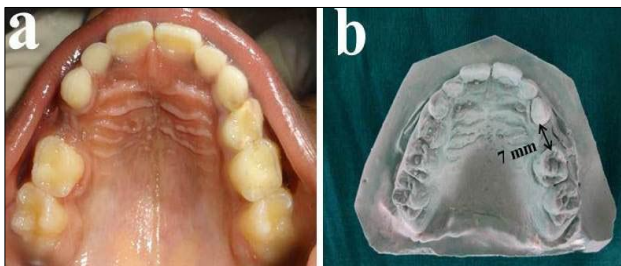


Figure 3a: postoperative photograph of the patient showing the space regained. Figure 3b: photograph of the maxillary study model showing 7 mm space present between the maxillary left primary canine and primary second molar postoperatively.

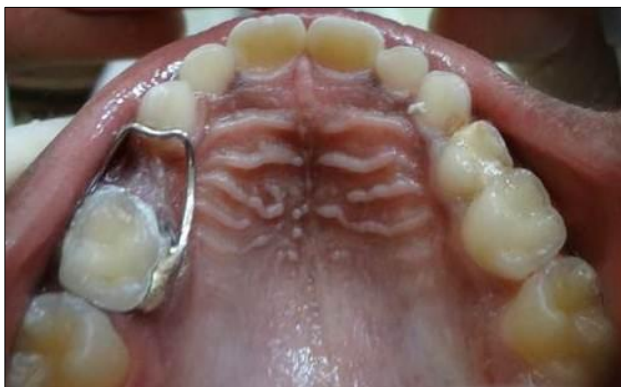

Figure 4: intraoral photograph showing cemented band and loop for further space maintenance.

DISCUSSION

The early loss of primary molars, causes a reduction in the arch length by mesial movement of the permanent first molar, if space maintainers are not used.⁵ For most children 7-10 years proves to be best for regaining lost arch space. This earlier distalisation has the advantage that the roots of the permanent first molar are incomplete, and orthodontic tipping or bodily movement is easier.² It is feasible to recover the lost space by distal movement of the permanent first molar by space regainers which are broadly divided into fixed and removable type.

The removable type space regainers use springs or screws incorporated in a Hawley's appliance. Distalisation of one tooth is achieved, with a longer span of treatment time and also they have the disadvantage of requiring patient compliance. Hence, it was decided to go for a fixed space regainer.

A literature search revealed that the methods of space regaining were conventionally used to regain space loss due to premature exfoliation of primary second molar, and thereby mesial migration of permanent first molar. In the present case, there was a need to distalise the primary second molar as well as the permanent first molar to regain space for the eruption of the first premolar. Therefore, it was decided to go ahead with the treatment using an appliance more 'springy' and 'elastic' enough to distalise two teeth, i.e. maxillary left primary second molar and permanent first molar. Hence, the available option to us was NiTi springs.

NiTi coils exhibit a long range of superelasticity with minimum load fluctuation despite large deflection due to excellent spring back and superelasticity.⁶ Due to this property, it is possible to achieve large tooth movements without having to replace the springs.⁴ Since there is inconclusive evidence on the tooth movements that occur when the appliances are used unilaterally for distalising two teeth, the double banded space regainer by Chalakka P was used in our case.⁴

Approximately 1 mm per month distal movement has been reported for permanent first molars, but then again there is distinct individual variation.⁷⁻¹¹ In the present case a space of 2.5mm had been regained within the total treatment time of two months, and there was a need to change the springs once within this treatment duration, which could be due to the fact that two teeth were to be moved. Distalizing the permanent first molar was possible without difficulty in the present case because the root formation was incomplete, and also no observable tipping was present. According to Chalakka P et al, there was no observable tipping on the permanent first molar in their case as well, because both the teeth adjacent to prematurely exfoliated primary teeth were banded for space regaining. This was the advantage of the DBSR over the conventionally used Gerber space regainer, where only one of the two teeth adjacent to space loss is banded allowing a possibility for tipping.⁴ Once the

desired space was achieved, the appliance was replaced with a short band and loop.

CONCLUSION

An early interception of the developing malocclusion by timely intervention can prevent its progression to a more complicated dentoskeletal problem, requiring extensive treatment in later stage of maturity of the child. The current case has described the judicious use of a new technique of DBSR with slight modifications to distalise two teeth, which can be used by the clinicians in practice management.

REFERENCES

1. Graber. Treatment of patients in the mixed dentition. In: Grabers Orthodontics current principles and techniques. 4th ed. Elsevier mosby publishers.2005 Pg 545.
2. Singh G. Interceptive orthodontic procedures. In: Textbook of orthodontics. 2nd ed. Jaypee brothers medical publishers Pg 557-559.
3. Damle SG. Space management. In: Textbook of pediatric dentistry. 4th edition. Arya medi publishing house. Pg 341.
4. Chalakka P, Thomas AM, Akkara F, Pavaskar R. New design space regainers: 'Lingual arch crossbow' and 'Double banded space regainer'. J Indian Soc Pedod Prev Dent 2012; 30 (2): 161-5.
5. Bhalajhi SI. Interceptive orthodontics. In: Orthodontics the art and science. 3rd ed. Arya Medi publishing house. 2006 Pg 234.
6. Miura F, Mogi M, Ohura Y, Karibe M. The super-elastic Japanese NiTi alloy wire for use in orthodontics. Part III studies on the Japanese NiTi alloy coil springs. Am J Orthod Dentofacial Orthop 1988;94:89-96.
7. Bondemark L, Karlsson I. Extraoral vs intraoral appliance for distal movement of maxillary first molars: A randomized controlled trial. Angle Orthod 2005;75:699-706.
8. Papadopoulos MA, Mavropoulos A, Karamouzos A. Cephalometric changes following simultaneous first and second maxillary molar distalization using a non-compliance intraoral appliance. J Orofac Orthop 2004;65:123-36.
9. Bondemark L. A comparative analysis of distal maxillary molar movement produced by a new lingual intra-arch Ni-Ti coil appliance and a magnetic appliance. Eur J Orthod 2000;22:683- 95.
10. Paul LD, O'Brien KD, Mandall NA. Upper removable appliance or Jones jig for distalizing first molars? A randomized clinical trial. Orthod Craniofac Res 2002;5:238-42.
11. Gianelly AA. Distal movement of the maxillary molars. Am J Orthod Dentofacial Orthop 1998;114:66-72.

Source of Support: Nil
Conflict of Interest: Nil